

ORIGINAL RESEARCH ARTICLE

Potential of the Gastroprotective Effect of Ranitidine by Verapamil in Ethanol-Induced Ulcer in Rats

Zeineb Sharif and Aisha Dugani*

Department of Pharmacology and Clinical Pharmacy, Faculty of Pharmacy, University of Tripoli, Libya

Received 08May 2013; Revised 14Aug 2013; Accepted 24Aug 2013

ABSTRACT

Peptic ulcer is a serious illness of the gastrointestinal tract (GIT) with many factors attributing to its etiology such as the use of nonsteroidal anti-inflammatory drugs (NSAIDs), smoking, alcohol, infection with *Helicobacter pylori*, imbalance between mucosal aggressive factors (acid and pepsin) and protective factors (mucus, blood flow and local prostaglandins). Several reports have indicated the importance of calcium ions in stimulating gastric acid secretion and the reversal of this effect by calcium channel blockers. This study was aimed to evaluate the effects of the combined administration of a calcium channel blocker, Verapamil (8 and 16 mg/kg, i.p) with the antiulcer drug belonging to the class of H₂-receptor antagonist, Ranitidine (50 mg/kg, p.o) on the gastric lesions induced by ethanol in rats. The effects of coadministration of verapamil and ranitidine on gastric volume, total gastric acidity and gastric mucosal mucus content were also studied. The results showed that verapamil used alone or combined with ranitidine provided a gastroprotective effect against ethanol-induced gastric ulcer. The gastroprotective effect was associated with an increase in gastric mucus content and a significant reduction in total gastric acidity. We conclude that the calcium channel blocker, verapamil, possesses an anti-ulcer effect and it is capable of potentiating the gastroprotective effect of ranitidine, therefore its use may be beneficial in patients suffering of peptic ulcer and cardiovascular diseases.

Key words: Gastroprotective, Calcium channel blockers, Verapamil, Ranitidine.

INTRODUCTION

Peptic ulcer disease (PUD) is a common disorder of the gastrointestinal tract associated with disruption of the lining of the stomach or duodenum. If peptic ulcers are found in the stomach, they are called gastric ulcers. If they are found in the duodenum, they are called duodenal ulcers^[1].

The disease usually results from an imbalance between defensive factors, such as secretion of mucus, bicarbonate, local prostaglandins, maintenance of adequate blood flow and the offensive factors, such as the production of acid and pepsin^[2].

Several studies have demonstrated the acid stimulating ability of calcium ions and there have been reports which link conditions with elevated levels of plasma calcium such as hyperparathyroidism, hypercalcemia and increased incidence of gastric acid secretion and peptic ulcer^[3,4]. Calcium is a potent stimulus for

gastric secretion in patients with gastrin secreting tumors such effect is due to its ability to potentiate the response to gastrin and stimulating the release of gastrin from non-beta cell tumors. The acid response to calcium infusion may be a useful screening test for the Zollinger-Ellison syndrome^[5].

Previous reports have indicated that the calcium channel blockers nifedipine and diltiazem provided a dose-dependent protection of the gastric mucosa against stress, Indomethacin, pyloric ligation and absolute ethanol-induced ulceration^[6- 8]. The results on the effectiveness of the calcium channel blocker verapamil in the prevention of gastric ulcers are contradictory. Verapamil has been reported to attenuate gastric ulceration and to inhibit gastric acid secretion in stress- and aspirin-induced gastric ulcer^[6, 9, 10], but to aggravate ethanol-induced ulcers^[6, 11].

Histamine receptor type 2 antagonists such as ranitidine, cimetidine and famotidine are widely used in human peptic ulcer disease. Jan *et al*^[12], using carbachol-induced ulceration model in rats found that the reduction in gastric volume and acidity obtained with the combination of verapamil and ranitidine was greater than when each drug is given alone. Bhave *et al*^[13] reported that simultaneous administration of low doses of the slow- and long- acting calcium channel blocker, amlodipine with either famotidine or omeprazole produced significant antiulcer effects in pylorus-ligated rats, as reflected by the reduction of volume of gastric secretion, acidity and ulcer index.

In this study we aimed to evaluate the gastro-protective effects of the combined administration of verapamil and ranitidine on ethanol-induced ulceration in rats. Both incidence, defined as the mean number of ulcers per rat, and the severity, defined as the cumulative length (mm) of ulceration were recorded. The gastric volume, total gastric acidity and mucus production were also determined.

MATERIALS AND METHODS

ANIMALS:

Male Albino Wistar rats (bred at the Animal Care Unit, Department of Pharmacology and Clinical Pharmacy, Faculty of Pharmacy, University of Tripoli, (Tripoli-Libya) weighing 160-320g, were used in the study. They were housed in an ambient temperature of 23°C with a 12/12 hr light-dark cycle. Animals were fed a balanced diet and given free access to water. Animals were deprived of food but allowed access to water for 24 hr prior to all experiments. The study was approved by the Faculty of Pharmacy and the experiments were done according to the ethics guidelines of the University.

DRUGS AND CHEMICALS:

Ranitidine hydrochloride (Sigma-Aldrich, Germany) was dissolved in distilled water. The other drugs and chemicals used in this study were verapamil (Sopharma-Bulgaria), Alcian blue dye (Northampton, U.K). All the other chemicals were of analytical grade and purchased from Merck (E. Merck, F.R. Germany) and (BDH Chemicals Ltd., Poole, England).

ETHANOL-INDUCED GASTRIC ULCERS:

Fasted rats were given an oral dose of absolute ethanol (1 ml/200 g)^[14], 30 min later the rats were killed by exposure to chloroform. A midline abdominal incision was made and the stomach

rapidly removed after ligating both the esophageal and pyloric ends. Each stomach was opened along the greater curvature; its content was drained and completely recovered by washing with 10 ml isotonic saline. Each stomach was pinned flat on paraffin wax-filled Petri dish and examined for ulcers using a hand lens (X10). The stomach was then examined for ulcers per stomach as well as the length of ulcers (expressed in millimeters) were recorded^[14]. Petechial lesions were counted; each five petechial lesions were taken as 1 mm of ulcer.

EXPERIMENTAL PROTOCOL:

Rats were randomly divided into 7 groups (n=6 in each group) and treated as follows:

Group 1: Sham control (given 1 ml distilled water only)

Group 2: Control ulcer (given 1 ml /200g absolute ethanol)

Group 3: Ranitidine (50 mg / kg) + Ethanol (1ml/200g)

Group 4: Verapamil (8 mg / kg) + Ethanol (1ml/200g)

Group 5: Verapamil (16 mg /kg) + Ethanol (1ml/200g)

Group 6: Ranitidine (50 mg / kg) + Verapamil (8 mg / kg) + Ethanol (1ml/200g)

Group 7: Ranitidine (50 mg /kg) + Verapamil (16 mg /kg) + Ethanol (1ml/200g)

Ranitidine was given orally to groups (3, 6, 7) 1 hr before ethanol administration. Verapamil was injected intraperitoneally to groups (4, 5, 6, and 7) 30 min before ethanol administration. One hour following ethanol administration all animals were killed by overdose of chloroform. The gastric ulcers, gastric content and mucus concentrations were determined.

DETERMINATION OF GASTRIC CONTENTS:

The contents of the stomach were collected the volume of gastric juice measured then the recovered solution was centrifuged (Heraeuslabfuge 400) at 3500 rpm for 10 min, the supernatant was taken and used for acid determination. One ml of the supernatant was completed to 50 ml with distilled water and titrated against 0.01N NaOH, using phenolphthalein as an indicator. Acid content was expressed as μEq per 100 g body weight^[15].

DETERMINATION OF GASTRIC MUCUS:

The modified procedure of Corneet *et al*^[16] was used for the determination of gastric mucus content. The glandular portion of the stomach was

carefully separated from the rumenal part, weighed and then transferred into 10 ml alcian blue solution [containing alcian blue 1.0 g/l, sucrose 0.16 mol/l, and sodium acetate 0.05 mol/l and finally adjusted to pH 5.8 with acetic acid]. The tissue was allowed to stain for 2 hr in alcian blue solution. To remove the unbound dye, the sample was washed for 15 min and then 45 min in 10 ml solution of 0.25 mol sucrose/l. The mucus-bound dye was eluted by immersing the mucosa in 10 ml of 0.5 mol $MgCl_2$ /l for 18 hr in a refrigerator. The eluate was extracted with 10 ml of diethyl ether, and the absorbance of the solution was measured using a spectrophotometer (Jenway Model 6300) at 605 nm. The amount of alcian blue extracted from the tissue was analyzed against a standard curve which was obtained from known graded concentrations (5-50 mg/l) of alcian blue solutions. The results were expressed as μg alcian blue/g wet tissue^[16].

STATISTICAL ANALYSIS

The results are expressed as mean \pm S.E.M. and sequential differences among the means were calculated at the level of $p < 0.05$ using student-t test.

RESULTS

EFFECTS OF CO-ADMINISTRATION OF VERAPAMIL AND RANITIDINE ON THE NUMBER AND LENGTH OF GASTRIC ULCERS INDUCED BY ETHANOL IN RATS:

The macroscopic appearance of the gastric mucosa in the sham control group and in rats pretreated with 8 and 16 mg/kg verapamil alone and in combination with ranitidine are shown in **Figure 1**, A, C, D, E, F and G, respectively. Intra-gastric administration of absolute ethanol to fasted rats resulted in severe gastric damage consisted of elongated bands 5-30 mm long (**Figure 1B**). The lesions were located mostly in the corpus (the portion of the stomach secreting acid and pepsin).

Ranitidine, when used alone, did not significantly reduce the number of ulcers induced by ethanol. Verapamil, on the other hand, significantly reduced the number of ulcers in a dose-dependent manner as compared to negative control (ethanol-treated group) (**Figure 2**). This effect was more prominent with a verapamil dose of 16 mg/kg ($p < 0.01$) than at a lower dose of 8 mg/kg ($p < 0.05$). The mean number of ulcers was 5.2 ± 0.7 , 5.7 ± 1.3 and 10.8 ± 1.3 respectively. Verapamil at the doses of 8 and 16 mg/kg showed more protection against gastric ulcers than

ranitidine (positive control), though the difference was not statistically significant (**Figure 2**).

The coadministration of verapamil with ranitidine resulted in a dose-dependent reduction in the number of ulcers induced by ethanol. Verapamil (16 mg/kg) plus ranitidine (50 mg/kg) produced a highly significant reduction in the number of ulcers ($p < 0.001$) compared to negative control group. A less significant reduction ($p < 0.01$) was obtained at the dose of 8 mg/kg. The mean number of ulcers was 1.2 ± 0.4 , 4.2 ± 0.7 and 10.8 ± 1.3 .

When comparing the results of the coadministration of Verapamil plus ranitidine to those of ranitidine alone, only the higher dose of verapamil (16 mg/kg) demonstrated a significant reduction ($p < 0.05$) in the number of ulcers. The smaller dose of verapamil (8 mg/kg) insignificantly reduced the number of ulcers relative to verapamil 8 mg/kg plus ranitidine group (4.2 ± 0.7 and 5.7 ± 1.3 respectively) (**Figure 2**).

Concerning the effects of treatment with verapamil and ranitidine on the length of gastric ulcers induced by ethanol. No significant difference was found in the length of ulcers in the ranitidine treated group as compared to ethanol-treated (negative control) group (**Figure 2**). Moreover, the length of the ulcers was increased in the ranitidine group.

Verapamil has increased the cumulative length (severity) of the ulcers induced by ethanol. It was interesting to note that verapamil at a smaller dose 8 mg/kg had a more potent and significant ($p < 0.05$) increase in the length of ulcers compared to negative control group treated with ethanol alone. On the other hand, the higher dose of verapamil (16 mg/kg) produced a slightly less increase in ulcer length than the smaller dose of 8 mg/kg, compared to ethanol-treated group (and 10.4 ± 1.2 , 11.8 ± 1.2 and 7.1 ± 0.8 respectively) (**Figure 2**).

In the group of animals administered a combination of ranitidine plus verapamil the reduction in the length of ulcers was highly and significantly ($p < 0.01$) reduced by the large dose of verapamil (16 mg/kg) given with ranitidine as compared to the smaller dose of verapamil (8 mg/kg) (4.5 ± 0.8 and 14.3 ± 1.7 respectively).

This combination also demonstrated a significant ($p < 0.05$) reduction in ulcer lengths compared to ranitidine only-treatment group, verapamil alone in doses of 8 and 16 mg/kg (4.5 ± 0.8 , 9.3 ± 0.8 , 11.8 ± 1.2 and 10.4 ± 1.2 respectively) (**Figure 2**).

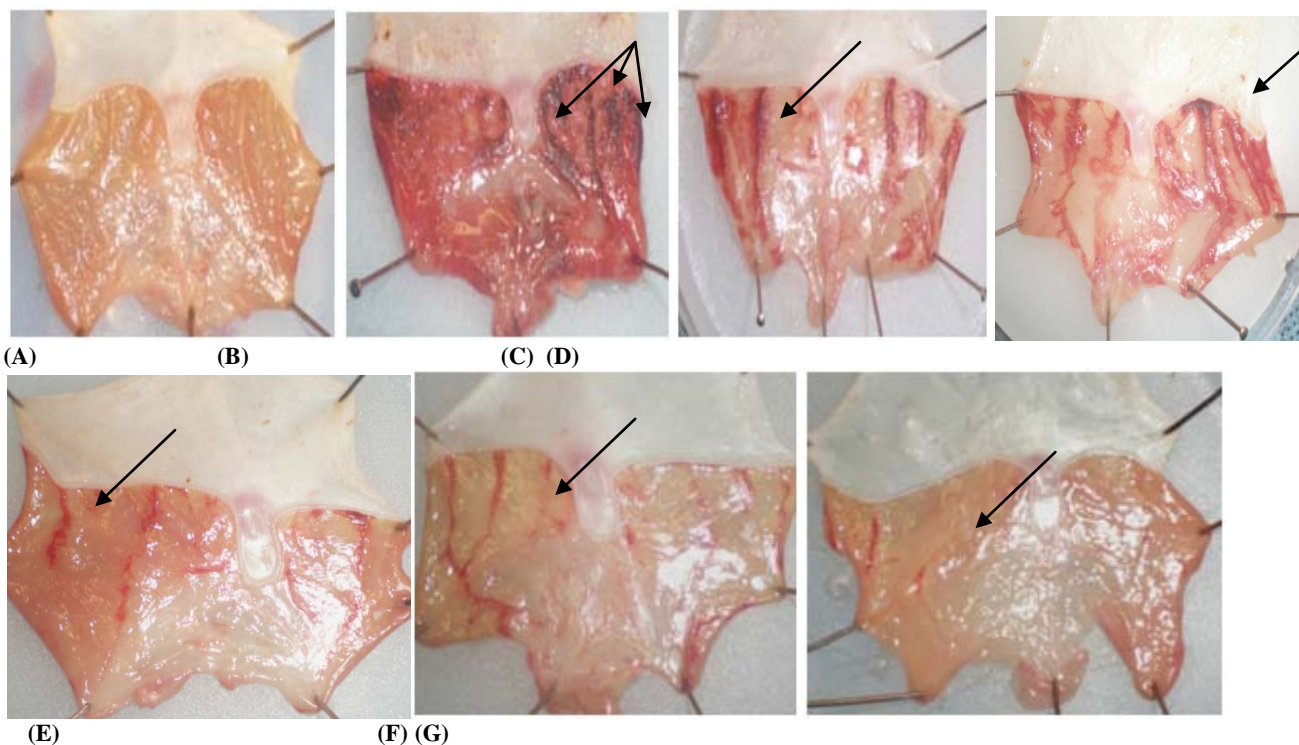


Figure 1: Macroscopic appearance of gastric mucosal lesions of rats from different treatment groups. (A) Rats in the sham control group showing normal mucosa. (B) The positive control group (treated with 1ml/200g absolute ethanol) showing gastric mucosa with multiple hemorrhagic lesions (black arrows). (C) The ranitidine (50 mg/kg) group showing milder lesions (black arrow). (D) Rats pretreated with Verapamil (8 mg/kg) showing moderate injuries of the gastric mucosa. (E) Pretreated with Verapamil (16 mg/kg) showing mild gastric lesions. (F) Pretreated with a combination of ranitidine (50 mg/kg) and verapamil (8 mg/kg) showing mild-moderate lesions.(G) Combined treatment of ranitidine (50 mg/kg) and Verapamil (16 mg/kg) showing noticeable protection of the gastric mucosa.

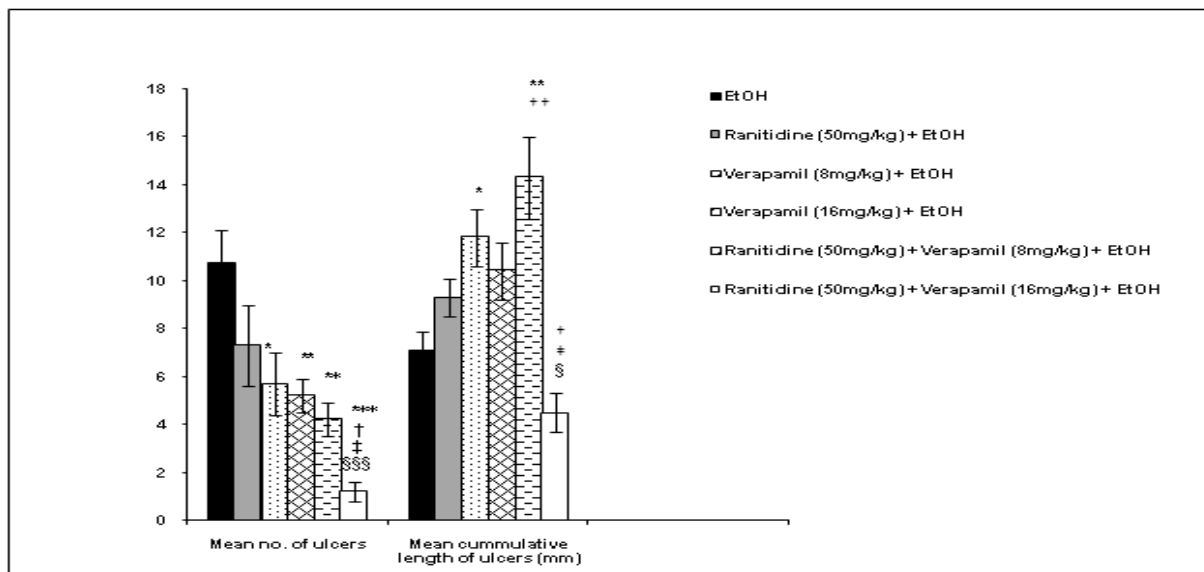


Figure 2: Effects of co-administration of Verapamil and ranitidine on the number and length of ethanol-induced gastric ulcers in rats. Data are expressed as the mean \pm SEM (n=6). * $p < 0.05$, ** $p < 0.01$, *** $p < 0.001$ vs. EtOH-treated group; † $p < 0.05$, †† $p < 0.01$, ††† $p < 0.001$ vs. Ranitidine (50 mg/kg, positive control group); ‡ $p < 0.05$, ‡‡ $p < 0.01$, ‡‡‡ $p < 0.001$ vs. Verapamil only (8 mg/kg); § $p < 0.05$, §§ $p < 0.01$, §§§ $p < 0.001$ vs. Verapamil only (16 mg/kg); ^ $p < 0.05$, ^^ $p < 0.01$, ^^ $p < 0.001$ vs. Verapamil (8mg/kg) + Ranitidine (50 mg/kg).

EFFECTS OF CO-ADMINISTRATION OF VERAPAMIL AND RANITIDINE ON THE VOLUME AND TOTAL GASTRIC ACIDITY IN RATS TREATED BY ABSOLUTE ETHANOL:

Groups treated with ethanol (negative control), ranitidine alone, verapamil alone (8 and 16 mg/kg) and combined with ranitidine, all showed

a highly significant ($p < 0.001$) increase in volume of gastric secretions compared with the sham group. The mean volume of gastric content was 2.87 ± 0.38 , 3.38 ± 0.25 , 3.28 ± 0.49 , 2.56 ± 0.17 , 2.50 ± 0.16 , 2.04 ± 0.12 and 0.22 ± 0.08 respectively. The dose of verapamil of 16 mg/kg administered alone and lower dose of verapamil in combination with ranitidine produced a significant

($p < 0.05$) reduction in volume of gastric content when compared to ranitidine only group. The combined administration of the highest dose of verapamil (16 mg/kg) with ranitidine provided the highest reduction ($p < 0.01$) in the volume of gastric content compared to ranitidine alone. Verapamil (16 mg/kg) plus ranitidine provided a highly significant ($p < 0.01$) reduction in gastric volume in comparison to the corresponding group given verapamil only (**Table 1**).

Intragastric administration of ethanol produced a highly significant ($p < 0.001$) increase in total gastric production compared to sham group given distilled water (600.0 ± 43.8 and 190.0 ± 12.4 respectively). Ranitidine showed a significant reduction ($p < 0.001$) in gastric acidity compared to ethanol-treated group (150 ± 6.8 and 600 ± 43.8). Both doses of Verapamil used in this study (8 and 16 mg/kg) when administered alone and in combination with ranitidine showed a potent and

significant reduction ($p < 0.001$) of total gastric acidity compared to the negative control group treated with ethanol (**Table 1**).

Verapamil administered alone produced an increase in total gastric acidity compared to ranitidine group (positive control). The increase was highly significant ($p < 0.001$) at the higher dose of 16.0 mg/kg (252.2 ± 4.8 and 150.0 ± 6.8 respectively) (**Table 1**).

The results were completely different when verapamil was used in combination with ranitidine. Both doses of verapamil plus ranitidine (50 mg/kg) produced a highly significant reduction ($p < 0.001$) in total gastric acidity compared to positive and negative control groups. The smaller dose of verapamil (8 mg/kg) showed the most significant reduction in gastric acidity compared to controls and to corresponding dose without ranitidine (99.8 ± 3.5 and 168.2 ± 12.4) (**Table 1**).

Table 1: Effect of co-administration of verapamil and ranitidine on the volume and total gastric acidity in rats

Treatment	Volume of gastric content (ml)	Total acid ($\mu\text{Eq}/100 \text{ g b.wt}$)
Sham (distilled water)	0.22 ± 0.08	190 ± 12.4
Control (EtOH)	$2.87 \pm 0.38^{\text{€€€}}$	$600 \pm 43.8^{\text{€€€}}$
Ranitidine (50 mg/kg)+EtOH	$3.38 \pm 0.25^{\text{€€€}}$	$150 \pm 6.8^{\text{€***}}$
Verapamil (8 mg/kg)+EtOH	$3.28 \pm 0.49^{\text{€€€}}$	$168.2 \pm 12.4^{\text{***}}$
Verapamil (16 mg/kg)+EtOH	$2.56 \pm 0.17^{\text{€€}}$	$252.2 \pm 4.8^{\text{€€€***,†††,‡‡‡}}$
Ranitidine (50 mg/kg)+Verapamil (8 mg/kg)+EtOH	$2.50 \pm 0.16^{\text{€€€†}}$	$99.8 \pm 3.5^{\text{€€€***,†††,‡‡‡,§§§}}$
Ranitidine (50 mg/kg)+ Verapamil (16 mg/kg)+ EtOH	$2.04 \pm 0.12^{\text{€€€††,§,^^}}$	$116.8 \pm 5.3^{\text{€€€***,††,‡‡,§§§}}$

Data are expressed as the mean \pm SEM (n=6). $^{\text{€}}$ $p < 0.05$, $^{\text{€€}}$ $p < 0.05$, $^{\text{€€€}}$ $p < 0.05$ vs. Sham (distilled water group), $^{\text{.}}$ $p < 0.05$, $^{\text{**}}$ $p < 0.01$, $^{\text{***}}$ $p < 0.001$ vs. EtOH-treated group; $^{\text{†}}$ $p < 0.05$, $^{\text{††}}$ $p < 0.01$, $^{\text{†††}}$ $p < 0.001$ vs. Ranitidine (50 mg/kg, positive control group); $^{\text{‡}}$ $p < 0.05$, $^{\text{‡‡}}$ $p < 0.01$, $^{\text{‡‡‡}}$ p vs. Verapamil only (8 mg/kg); $^{\text{§}}$ $p < 0.05$, $^{\text{§§}}$ $p < 0.01$, $^{\text{§§§}}$ $p < 0.001$ vs. Verapamil only (16 mg/kg); $^{\text{^}}$ $p < 0.05$, $^{\text{^^}}$ $p < 0.01$, $^{\text{^^^}}$ $p < 0.001$ vs. Verapamil (8mg/kg) + Ranitidine (50 mg/kg).

EFFECTS OF CO-ADMINISTRATION OF VERAPAMIL AND RANITIDINE ON GASTRIC WALL MUCUS CONTENT IN RATS TREATED WITH ABSOLUTE ETHANOL:

The mucosal mucin content was highly and significantly reduced ($p < 0.001$) in all treatment groups as compared to sham control group administered distilled water. The reduction in mucin content was the highest in the negative control group treated with absolute ethanol alone compared to sham control group (79.8 ± 4.5 and 155.5 ± 7.9 ; $p < 0.001$) (**Table 2**).

Ranitidine (50 mg/kg) given alone, significantly ($p < 0.001$) augmented the gastric mucin content as compared to ethanol-treated group (106 ± 2.7 and 79.8 ± 4.5).

There was a slight but insignificant increase in mucosal wall mucin content in the groups of

animals treated with verapamil alone (8 and 16 mg/kg) and in combination with ranitidine (50 mg/kg) in comparison to ethanol-treated (negative control) group. On the other hand, all treatment groups given verapamil alone or combined with ranitidine showed a significant reduction in mucin content as compared to ranitidine (positive control) group. The significance was higher in combination groups ($p < 0.001$) and less in groups treated with verapamil only at both doses of 8 and 16 mg/kg (**Table 2**).

Table 2: Effect of coadministration of verapamil and ranitidine on gastric wall mucus content in rats treated with absolute ethanol

Treatment	Mean Mucus Production ($\mu\text{g/g}$ wet tissue)
Sham (distilled water)	155.5 ± 7.9
Control (EtOH)	$79.8 \pm 4.5^{\text{€€€}}$
Ranitidine (50 mg/kg)+EtOH	$106.0 \pm 2.7^{\text{€€€***}}$
Verapamil (8 mg/kg)+EtOH	$86.0 \pm 2.2^{\text{€€€†††}}$
Verapamil (16 mg/kg)+EtOH	$91.4 \pm 3.6^{\text{€€€†††}}$
Ranitidine (50 mg/kg)+Verapamil (8 mg/kg)+EtOH	$82.5 \pm 6.4^{\text{€€€††}}$
Ranitidine (50 mg/kg)+ Verapamil (16 mg/kg)+ EtOH	$86.3 \pm 3.9^{\text{€€€††}}$

DISCUSSION

The usefulness of ethanol ulcers as a screen method for antiulcer activity is well recognized. Absolute ethanol administered orally can produce gastric mucosal ulcerations of uniform severity in 1 hr in a reliably high percentage of animals^[17].

In this study, we have applied this type of screening test because of the simplicity and ease with which it can be performed. Moreover, this type of ulceration is thought to be caused primarily by the direct damaging action of ethanol on the gastric mucosa (particularly blood vessels).

The molecular mechanisms of ethanol-induced gastric injury have not yet been completely known. However, several factors including generation of oxygen derived free radicals, lipid peroxidation, gastric acid back diffusion, genetic damage, submucosal vasodilatation, release of inflammatory mediators, and decreased prostaglandin content are proposed to be involved in the pathway^[17-20].

Calcium channel blocking agents like verapamil, nifedipine, and diltiazem are commonly used in the management of cardiovascular diseases including hypertension, angina, myocardial infarction and supraventricular tachycardia^[21].

Several studies have shown a protective effect of calcium channel blockers on experimentally-induced gastric ulcers^[22]. However, the mechanism (s) underlying the protective effects of these drugs against gastric damage are unclear.

The aim of the present study was to investigate the extent to which verapamil; the calcium channel antagonist may interact with the histamine 2 receptor antagonist ranitidine in the prevention of ethanol-induced gastric ulcers.

In our study, we have found that verapamil reduced the number of ulcers in a dose-dependent manner, verapamil at the doses of 8 and 16mg/kg showed more protection than ranitidine (positive control) against gastric ulcers in rat. Ranitidine did not significantly reduce the number of ulcers induced by ethanol when used alone.

In fact, ranitidine having an inhibitory action on gastric secretion have been proven to be entirely ineffective in the prevention of ethanol ulcers, since the pathogenesis of ethanol-induced gastric damage was independent of gastric pH^[23].

This protective effect of verapamil on gastric ulcer is partially in agreement with a previous study by Kilic FS *et al*^[24], who reported that only the high dose of verapamil of 25 mg/kg has reduced the

number of ulcers while low doses of 1mg and 5mg/kg were ineffective in reducing ethanol-induced gastric lesions.

Other reports have indicated that verapamil at doses 4, 8, 16 and 32 mg/kg produced a significant protection against gastric ulcers induced by aspirin and pyloric ligation; however the protective effect did not exhibit dose dependency in these models^[25]. Moreover, Manda *et al*^[26] have shown that verapamil in a dose of 1mg/100g significantly reduced number of gastric ulcers in restraint and aspirin induced models.

Our results have demonstrated that the co-administration of verapamil at doses 8 and 16 mg/kg with ranitidine (50 mg/kg) resulted in a dose-dependent reduction in the number of ulcers induced by ethanol. This reduction in number of ulcers was greater than that obtained with the positive control given ranitidine alone. Therefore, verapamil seems to potentiate the gastroprotective effect of ranitidine. It has been reported that Verapamil can potentiate the anti-ulcer effect of the histamine H₂-receptor antagonist drug Famotidine in restraint and aspirin induced models of gastric ulcers^[26]. Another study by Bhave and Bhatt^[13] have indicated that a combined treatment consisting of long-acting calcium channel blocker, amlodipine 0.25mg/kg and a H₂ receptor antagonist famotidine 1mg/kg produced a significant reduction in the number of ulcers as compared to the groups received either famotidine or amlodipine alone.

The protective effect of the calcium channel blocker verapamil on gastric ulcers was explained by its ability to inhibit calcium-dependent pathway and by its effect to antagonise the injurious effect of histamine and other biogenic amines on the capillaries of gastric mucosal barrier^[27]. It is possible therefore, that ranitidine and verapamil act by two or more separate mechanisms and when co-administered in low doses caused a potentiating effect that was reflected as a reduction in the number of ulcers in this model.

In addition, our study showed that pre-treatment with ranitidine has no effect on the severity of ethanol-induced gastric ulcers usually expressed as the cumulative length of these ulcers in millimetres. Verapamil alone augmented the severity of gastric lesions and this result is in agreement with that reported by Saravanakumare *et al*^[28], Glavin^[29], and Ghaneyem^[30], who

demonstrated an increase in the severity of aspirin, ethanol-induced gastric ulcers with acute treatment with calcium channel blockers verapamil and diltiazem. They explained such effect to be due to the fact that calcium channel blockers are associated with mild gastro intestinal irritation in the initial phase and these effects subside on prolonged administration.

Our data on gastric secretion showed that 1ml of absolute ethanol stimulated the gastric secretions when compared with sham group. This increase was statistically highly significant ($p < 0.001$). Verapamil alone at dose of 8, 16 mg /kg did not significantly affect the volume of gastric content when compared with positive control ranitidine and this indicate that verapamil at both doses is almost as effective as ranitidine in decreasing the gastric secretions. This result is in accordance with that reported by Jan^[31] who demonstrated that verapamil efficiently inhibited the volume of gastric content resemble that given by another H2 blocker cimitidine. Our study also showed that both doses of verapamil 8, 16 mg/kg, when co-administered with ranitidine, produced a significant reduction in the volume of gastric secretions, and verapamil at 16mg/kg with Ranitidine significantly decreased the volume of gastric juice when compared with verapamil 16mg/kg without ranitidine .

This study correlates with the findings of other workers who observed that ranitidine showed a significant reduction in total gastric acidity compared to ethanol-treated group^[32]. This is due to well-known H2-receptor antagonistic action of ranitidine with H2-receptor and inhibition of the activation of adenylatecyclase and as a result no cyclic AMP formation, which is required for HCl production. We observed a significant reduction of gastric acidity using verapamil alone at both doses of 8 and 16 mg/kg compared to the negative control group treated with ethanol alone. This result correlates with that of other workers who concluded that verapamil significantly reduced acid secretions^[32], also both doses of verapamil used in this study (8 and 16 mg/kg) when administered in combination with ranitidine showed a potent and significant reduction of total gastric acidity when compared to the positive control and negative control group treated with ethanol.

Verapamil, the well-known calcium channel blocker, may interfere with the H⁺,K⁺ ATP *ase* system which is accessible from luminal side of the stomach^[32]. Histamine is a potent stimulant of acid secretion and its release from peritoneal mast cells is critically dependent upon external Ca⁺⁺ concentration, so non availability of Ca⁺⁺ may

cause reduced effects of histamine on acid production in the stomach have found. Accordingly, Al-Mashhadani^{etal}^[7] have demonstrated that nifedipine was as effective as cimetidine in reducing stress-induced gastric ulcers with inhibition of mast cell de-granulation.

The mucosal mucin content was highly and significantly reduced ($p < 0.001$) in all treatment groups as compared to sham control group administered distilled water. The reduction in mucin content was the highest in the negative control group treated with absolute ethanol alone compared to sham control group. Ranitidine (50 mg/kg) given alone, significantly ($p < 0.001$) augmented the gastric mucin content as compared to ethanol-treated group.

There was a slight but insignificant increase in mucosal wall mucin content in the groups of animals treated with verapamil alone (8 and 16 mg/kg) and in combination with ranitidine (50 mg/kg) in comparison to ethanol-treated (negative control) group. On the other hand, all treatment groups given verapamil alone or combined with ranitidine showed a significant reduction in mucin content as compared to ranitidine (positive control) group. The significance was higher in combination groups. These results correlate with that reported by Ohnishi and others^[33], reported that HCO₃⁻ secretion was suppressed by addition of Ca⁺⁺ channel blocker verapamil ,and by the results of Quinton^[34], who showed that the presence of HCO₃⁻ in the medium is crucial for efficient stimulation of the release of mucin.

The production and secretion gastric mucins, which are high molecular weight glycoproteins produced in and secreted from specialized differentiated mucous cells, play an important role in the protection of gastric mucosa from acid – peptic injury. Mucins are synthesized in the Golgi apparatus and stored in intracellular granules which are transported to the luminal surface of the cell^[35], these mucin granules finally discharge their contents to the lumen, a process generally known as exocytosis. The first event in exocytosis is the fusion of a granule with the plasma membrane at the fusion pore, and this event is mediated by the exocytosis related proteins whose activities are regulated by the intracellular Ca⁺⁺ concentration, and protein kinase A and C^[36].

Taking into consideration that acid secretion and mucin production did not play a major role in ethanol-induced gastric ulcer model in rats and that other factors like reactive oxygen species

liberation may play a crucial role in the development of these lesions.

The gastroprotective effect of the calcium channel blocker Verapamil in this study may be related to its antioxidant properties related to its ability to decrease lipid peroxidation.

It has been shown that Ca^{++} channel blockers, nifedipine, flunarizine, verapamil and diltiazem, also have antioxidant action and that these compounds have erythrocyte membrane stabilizing and antiplatelet-aggregatory actions in rabbits^[37].

Gutiérrez-Cabano^[38] has shown that both endogenous prostaglandins and sulfhydryls of the gastric mucosa participate in verapamil protection against ethanol damage because the protective effect provided by verapamil was significantly diminished by pretreatment with indomethacin and iodoacetamide.

Fukuda *et al*^[39] have demonstrated that verapamil significantly increased PGE₂ and 6-keto PGF₁ alpha generation by the surface epithelial cells in vitro and that this increase was not affected by the addition of a calmodulin antagonist.

In conclusion, our results demonstrate that verapamil per se or combined with ranitidine enhanced the gastroprotective activity against ethanol-induced lesions in rats. This effect was accompanied by a significant reduction in total gastric acidity along with an increase in gastric wall mucus content which could play a part in the preventive effect of gastric lesions.

Further research is needed to establish the possible involvement of other mechanisms in providing such gastroprotection including: local prostaglandin production, mucosal blood flow and the release of inflammatory mediators. In addition, chronic and repeated treatment with verapamil may be tested to clarify the effects on severity of gastric lesions (cumulative length of ulcers).

The mechanism can be attributed to decrease in gastric acidity along with an enhancement of prostaglandin synthesis and antioxidant potential.

REFERENCES

1. Greene R, Harris N: Gastrointestinal and liver diseases. In: Kumar V, Cotran R and Robbins S, editors. Pathology and therapeutics for pharmacists. 7th ed. UK: Pharmaceutical press; 2000. P.298-382.
2. McQuaid KR, Isenberg JI. Medical therapy of peptic ulcer disease. SurgClin North Am 1992; 72(2):285-316.

3. Allerheiligen DA., Schoeber J, Houston RE, Mohl VK, Wildman KM. Hyperparathyroidism. Am Fam Physician 1998; 57(8):1795-1802.
4. Reeder DD, Jackson BM, Ban J, Clendinnen BG, Davidson WD, Thompson JC. Influence of hypercalcemia on gastric secretion and serum gastrin concentrations in man. Ann Surg 1970; 172(4): 540-546.
5. Basso N, Passaro E Jr. Calcium-stimulated gastric secretion in the Zollinger-Ellison syndrome. Arch Surg 1970; 101:399-402.
6. Glavin GB. Verapamil and nifedipine effects on gastric acid secretion and ulcer formation in rats. J Pharm Pharmacol. 1988; 40(7):514-5.
7. Al-Mashhadani WM, Karim KH, Al-Taie RI, Al-Zahawi HM. Nifedipine versus cimetidine in prevention of stress-induced gastric ulcers in rats. Eur J Pharmacol. 1991; 192(1):117-21.
8. Yong DG, Geng BQ, Li Y, Bi S. Antiulcer effect of diltiazem in rats. 1995;16(6):517-20.
9. Sunita MJ, Bhatt RV, Goyal RK, Santini DD, Parmar NS. Effect of verapamil on gastric ulcers in rats. Indian J Pharmacol 1990; 22: 253-256.
10. Ogle CW, Cho CH, Tong MC, Koo MW. The influence of verapamil on the gastric effects of stress in rats. Eur J Pharmacol. 1985; 112(3):399-404.
11. Glavin GB. Calcium modulators and the gut: an update. Calcium modulators and the gut: an update. Methods Find Clin Pharmacol 1992; 14(6): 465-7.
12. Jan M, Mughal MA, Tanwani RK, Aamir K, Ali M. Evaluation of combined effect of verapamil and ranitidine on the volume and acidity of carbachol induced gastric secretion. J Ayub Med Coll Abbottabad. 2004; 16(2):34-7.
13. Bhave AL, Bhatt JD, Hemavathi KG. Antiulcer effect of amlodipine and its interaction with H₂ blocker and proton pump inhibitor in pylorus ligated rats. Indian J Pharmacol 2006; 38(6): 403-407.
14. Szabo S. Mechanism of mucosal injury in the stomach and duodenum: time sequence analysis of morphologic, functional, biochemical and histochemical studies. Scan J Gastroenterol 1987; 22(Suppl.127):21-28.

15. Parmar NS, Desai JK. A review of the current methodology for the evaluation of gastric and duodenal antiulcer agents. *Indian J Pharmacol* 1993; 25:120-35.
16. Corne SJ, Morrissey SM, Woods RJ. A method for the quantitative estimation of gastric barrier mucuse. *J Physiol (London)* 1974; 242:116-7.
17. Yoshikawa T, Naito Y, Ued S, Oyamada H, Takemura T, Yoshida N, Sugino S. Role of oxygen-derived free radicals in the pathogenesis of gastric mucosal lesions in rats. *J Gastroenterol* 1990; 12: S65- S71.
18. Bagchi D, Carryl OR, Tran MX, Krohn RL, Bagchi DJ, Garg A, Bagchi M. Stress, diet and alcohol-induced oxidative gastrointestinal mucosal injury in rats and protection by bismuth subsalicylate. *J ApplToxicol* 1998; 18:3-13.
19. Naito Y, Yoshikawa T, Matsuyama K, Yagi N, Arai N, Nakamura Y, Nishimura S. Effects of oxygen radical scavengers on the quality of gastric ulcer healing in rats. *J ClinGatroenterol* 1995; 21:S82- S86.
20. Marotta F, Tajiri H, Safran P, Fesce E, Ideo G. Ethanol-related gastric mucosal damage: Evidence of a free radical-mediated mechanism and beneficial effect of oral supplementation with bionormalizer, a novel natural antioxidant. *Digestion* 1999; 60: 538-543.
21. Fleckenstein A. History of calcium antagonists. *Cir Res* 1983; 52(1) 3.
22. Bilici D, Banoğlu ZN, Kiziltunç A, Avci B, Ciftçioğlu A, BiliciS. Antioxidant effect of T-type calcium channel blockers in gastric injury. *Dig Dis Sci* 2002; 47(4):850-55.
23. Del Soldato P, Foschi D. Comparison of the gastric cytoprotective properties of atropine, ranitidine, and PGE2 in rats. *European J Pharmacol* 1984; 106 (1):53-58.
24. Kilic FS, Baser S, Oezlem B, Kevser E. Dose-dependent Effects of verapamil on ethanol-induced gastric lesions in rats. *J Health Sci* 2006; 52(6): 781-786.
25. Sunita J and Bhatt R. Effect of verapamil on gastric ulcers in rats. *Indian Journal of Pharmacology* 1990; 22:253-256.
26. Mandal S, Roy RK, Das HN, Aditya GN, Chattopadhyay RN, Lahiri HL and, Maitra SK. Potentiation of gastric antiulcer effect of famotidine by calcium channel blockers in rats. *Indian J Pharmacology* 1998; 30 (6): 390-393.
27. Rogers C, Szabo S. Role of calcium on acid secretion from the rat isolated gastric mucosa during stimulation with histamine, pentagastrin, methacholine, and dibutylr cyclic adenosine-3, 5-monophosphate. *Br J Pharmacol* 1978; 64:359-368.
28. Saravanakumar M, Revathi P, PrakashShyam K, Kadalmani B. Gastric ulcer productive property of calcium channel blockers in male albino rats. *Int J Pharma Bio Sci* 2011; 2: 629-636.
29. Glavin GB. Calcium channel modulators: effects on gastric function. *Eur J Pharmacol* 1989; 160(3):323-330.
30. Ghanayem BI, Matthews HB, Maronpot RR. Calcium channel blockers protect against ethanol- and indomethacin-induced gastric lesions in rats. *Gastroenterology* 1987; 92(1):106-111.
31. Jan M, Badar A, Comparison of verapamil and cimitidine for their effects on volume and acidity of carbachol induced gastric secretion in fasting rabbits. *J Ayub Med Coll Abbottabad* 2005; 17(3):11-14.
32. Kirkegaard P, Christianson J, Peterson B, Olsen PS. Calcium and stimulus-secretion coupling in gastric fundic mucosa: effect of inhibition of calcium transport by verapamil on gastric acid secretion in the isolated guinea pig fundic mucosa and in healthy subjects. *Scand. J. Gastroenterol* 1982; 17:533-538.
33. Ohnishi A, Shimamoto C, Katsu KI, Ito S, Imai YandNakahari T. EP1 and EP4 receptors mediate exocytosis evoked by prostaglandin E2 in guinea-pig antral mucous cells. *Experimental Physiology* 2004; 86(4): 452-460.
34. Quinton PM. Role of epithelial HCO3 transport in mucin secretion. *Am J Physiol* 2010; 299:C1222-C1233.
35. Forstner G, Zhang Y, McCool D, Forstner J. Regulation of mucin secretion in T84 adenocarcinoma cells by forskolin: relationship to Ca²⁺ and PKC. *Am J Physiol* 1994 ;266(4 Pt 1):G606-612.
36. Sudhof TC. The synaptic vesicle cycle: a cascade of protein-protein interactions. *Nature* 1995; 375, 645-653.
37. Robak J and Duniec Z: Membrane activity, antioxidant, anti aggregatory and anti-hemolytic properties of four calcium

- channel blockers. *Pharmacol Res Commun* 1986; 18: 1107-1117.
38. Gutiérrez-Cabano CA. Prostaglandins and sulfhydryls may mediate gastric protection induced by verapamil in rats. *Dig Dis Sci* 1993; 38(11):2043-2048.
39. Fukuda T, Arakawa T, Mach T, Durbin T, Tarnawski A. Calcium channel blockers and prostaglandin generation by gastric surface epithelial cells. *Prostaglandins* 1991; 42(6):587-597.