

RESEARCH ARTICLE

Study of the relation between testosterone levels and the severity of acne vulgaris among unmarried women at Al-Shati area, Libya

Abdullah Sheeba¹, Mrym Beshar¹, Ali Farag Hawad², Ambarka Barka³, Halema Fathi³

¹Department of Medical Lab Technology, Faculty of Engineering and Technology, Sebha University, Libya,

²Department of Biochemistry, Faculty of Medicine, Sebha University, Libya,

³Department of Physiology, Faculty of Science, Sebha University, Libya

Received: 02 Feb 2018; Revised: 23 Feb 2018; Accepted: 01 Mar 2018

ABSTRACT

Introduction: Acne vulgaris (AV) is long-lasting inflammatory illness of pilosebaceous unit and is clinically characterized by seborrhea and open and closed comedones, and in the severe cases, papules, pustules, nodules, deep pustules, and pseudocysts. The situation starts after adolescence and is a common skin disorder in adolescents and young grown person. **Aim:** The aim of this study was to evaluate the relation between testosterone levels and the states of AV among unmarried women. **Materials and Methods:** This study was conducted on 52 unmarried women, from which 26 women were with AV and 26 were used as control (age ranges were from 14 to 36 years). The patients were divided into three groups according to the severity of AV (sever, moderate, and mild). **Results:** Serum testosterone was significantly higher ($P < 0.05$) in severe and moderate acne patients, while the serum testosterone level shows no significant difference in females with mild acne disease when compared with that of female control group ($P > 0.05$). **Conclusion:** The conclusion of the study found a significant association between serum testosterone and severity of AV, and there was no correlation between the severity of AV and patients ages.

Keywords: Acne vulgaris, mild, moderate, pilosebaceous, severe, testosterone.

INTRODUCTION

Acne vulgaris (AV) is long-lasting inflammatory illness of pilosebaceous unit and is clinically characterized by seborrhea, open and closed comedones, papules, and pustules, and in severe cases nodules, deep pustules and pseudocysts. The situation starts after adolescence and is a common skin disorder in adolescents and young grown person.^[1] Acne is the most common illness of the skin which affects 20–90% of all adolescents, with spontaneous resolution, in most cases, in late teens or early twenties.^[1-3] It occurs predominantly on the face and to a lesser extent, and on the neck back and chest,^[2-4] it is also on shoulders and arms.^[5] It is marked by the blackheads papules, pustules, and nodules and scarring also; the etiology of AV was multifactorial, including genetic, hormonal, and bacteria. The cause of acne is still not fully

understood. However, there are four main factors that cause the formation of lesions in acne:^[6] Increased sebum production by the sebaceous glands, of which androgen has an important role;^[7] follicles hyperkeratinization, which causes an enlargement of microcomedone leading to blackheads formation;^[8] colonization of the follicle by anaerobic bacteria propionibacterium acnes; and inflammatory reactions.^[9] Each inflammation was preceded by the hyperkeratinization of follicles. Current therapies target the four factors above to control recurrence and long-term care.^[7-9] AV has a possible correlation between polycystic ovary syndrome and androgenism in females. Acne develops earlier in females than in males, and it often reflects early puberty. AV is an inflammatory disease of pilosebaceous glands. Severity of disease changes from one individual to other.^[10] Although excess sebum production is considered prerequisite for the development of acne, other factors involved in the pathogenesis include hypercornification of the pilosebaceous duct colonization of pilosebaceous duct with

*Corresponding Author:

Abdullah Najim Sheeba, Department of Medical Laboratories, University of Sabha, Libya.
E-mail: abo.taqui.2016@gmail.com

propionibacterium acnes and local release of inflammatory mediators.^[11] Acne subjects not merely excrete more sebum, the secretion rates have been seen to correlate well with the severity of acne.^[12] Androgens (total testosterone, androstenedione, and dehydroepiandrosterone sulfate) are involved in the development of acne.^[13] The skin is a typical target tissue for androgens and testosterone, a major androgen in human blood that stimulates many metabolic processes in the epithelium of sebaceous gland.^[14] Raised androgen levels (testosterone, androstenedione, dehydroepiandrosterone, and dehydroepiandrosterone sulfate) in women with acne have been repeatedly demonstrated in many studies. Androgens enhance the sebum, production, and follicular keratinization that plays the key role in the etiology of acne,^[15] whereas androgens participate in this process by inducing, in androgen-sensitive body sites, the transformation of thin, non-pigmented vellus hair to coarse, pigmented terminal hair which are under the influence of the androgens.^[16] The aim of this study was to evaluate the relation between testosterone levels and the states of AV in unmarried women.

MATERIALS AND METHODS

This study was conducted on 52 unmarried women, from which 26 women were with AV and 26 were used as control. Their age range was from 14 to 36 years. The patients were divided into three groups according to the severity of AV (severe, moderate, and mild), and patients who consume high energy diet or taking drugs, and those suffering from diseases during the study period were excluded from the study. This study was performed at Al-Shati region (in the period extended from April to October 2015). Blood samples were collected from all contributors in tubes without anticoagulant. Serum was separated by centrifugation of the blood samples at 3000 round per minute for 5 min and serum samples were kept at -20°C until used. The analysis for testosterone was performed according to the standard methods as in the sheet enclosed with the kit. The commercial kits used in this study were a product of General Biologicals Corporation company.^[17] The analysis was carried out with ELISA model A2 (2003), Italy. Minitab and Excel programs version 11 were used for statistical

analysis and graphic presentation. The paired t-test and ANOVA were used to compare between the patients and control. $P < 0.05$ was considered as statistically significant.

RESULTS

Table 1 and Figure 1, shown mean \pm standard deviation of testosterone levels in the serum of control and patients groups, the level of severe group was 4.2 ± 0.98 , the moderate group level was 3.0 ± 1.32 and the mild group level was 1.0 ± 1.66 . Serum testosterone was significantly higher in severe and moderate acne patients, these levels were highly significant compared with that of control group ($P < 0.05$), whereas the serum testosterone levels in females with mild acne vulgaris, show no significant difference when compared with that of the females control group ($P > 0.05$), as shown in the Table 2 and Figure 2. Table 2 and Figure 2 show the number of patients and control, twenty-six for each group (patients and control), and the levels of testosterone of patients and control were 2.7 ± 1.84 and 1.7 ± 1.13 , respectively. It showed statistically significantly difference when compared with control ($P < 0.05$). Table 3 shows the number of patients and their age

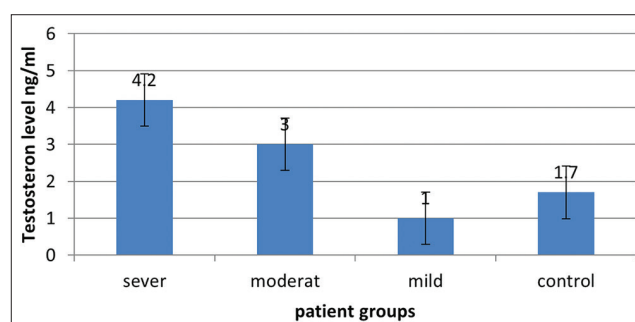


Figure 1: Testosterone levels for severe, moderate, and mild in acne vulgaris patients and control

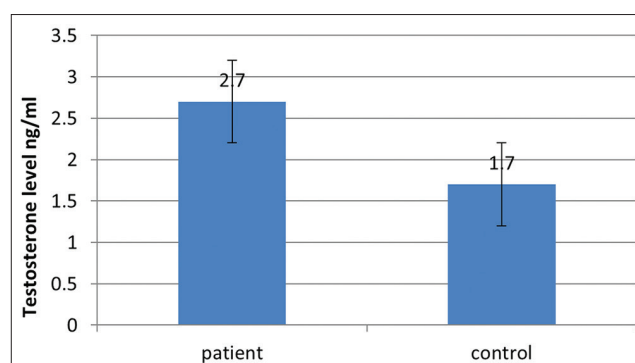


Figure 2: The mean \pm standard deviation. Serum levels of testosterone in female patients and control

Table 1: Testosterone levels for severe, moderate, and mild in acne vulgaris patients and control

Female	Testosterone (ng/ml)								
	Severe			Moderate			Mild		
	<i>n</i>	M±SD	<i>P</i>	<i>n</i>	M±SD	<i>P</i>	<i>n</i>	M±SD	<i>P</i>
Patients	8	4.2±0.98	0.00	10	3.0±1.32	0.01	8	1.0±1.66	0.26
Control	26	1.7±1.13		26	1.7±1.13		26	1.7±1.13	

M: Mean, SD: Standard deviation

Table 2: The M±SD. Serum levels of testosterone in female patients and control

Female	Testosterone (ng/ml)		
	<i>n</i>	M±SD	<i>P</i> -value
Patients	26	2.7±1.84	0.02
Control	26	1.7±1.13	

M: Mean, SD: Standard deviation

Table 3: Distribution of the severity of AV by age

Severity of AV	Severe (<i>n</i> =8)	Moderate (<i>n</i> =10)	Mild (<i>n</i> =8)
Age range (year)	18–32	15–36	14–27
Testosterone (ng/ml)	4.2±0.098	2.9±1.32	1.0±1.66

AV: Acne vulgaris

range according to the severity of AV, the number and average range of patient with severe AV were 8 and 18–32, respectively, whereas the number and average range of patients with moderate AV were 10 and 15–36, respectively, while the patients with mild AV, their number and average range were 8 and 14–27, respectively. Whereas, the mean ± standard deviation of testosterone level for patients with severe AV was 4.2 ± 0.98, and mean ± standard deviation of testosterone for patients with moderate and mild with AV was 2.9 ± 1.32 and 1.0 ± 1.66, respectively.

DISCUSSION

AV is a common disorder of the pilosebaceous follicles that affect the skin of the face, neck, upper part of the trunk, and back. Non-inflammatory and inflammatory acne lesions consist of open and/or closed comedones, papules, pustules, and nodules (preliminary evidence for Vitamin D deficiency in nodulocystic acne). It affects 85% of teenagers and 50% of persons between the ages of 20 and 30 years.^[18] The results of this study show a three distinct groups of AV: Mild, moderate, and severe, serum testosterone was significantly higher in severe acne and in moderate acne patients, research by Lawrence *et al.*^[19] mentioned that

free and total testosterone levels on plasma are significantly increased on the female with AV, and this finding was in agreement with the results of this study. Testosterone is the major androgen in human blood that encourages many metabolic processes in the epithelium of sebaceous gland,^[13] and raised testosterone levels in women with AV have been reported in many studies.^[12] The findings of this investigation were consistent with these reports, whereas the women with AV have elevated levels of testosterone, since androgen provocation sebum production and its excretion ability will result in the amassing of sebum in the definite sites of the body as described by Gollnick and Cunliffe^[19] and Baumann,^[20] this may explain the severity of AV, in the current study. Many factors such as uncontrolled diet, stress, hormonal factors such as menstrual abnormalities, exposure to ultraviolet light, trauma, smoking, and family history are likely to have an effect on the levels of pro-inflammatory cytokines, are factors aggravate the status of the AV which may lead to increase severity of clinical feature.^[17] According to the results of this study, the severity of AV can be at any age, and from the beginning of puberty till later of reproductive age, these results can indicate that AV depends on the levels of testosterone, rather than the age. The high testosterone levels in the women with AV have been repeatedly demonstrated in many studies.^[14] Polycystic ovarian syndrome affects 5–10% of the women in the reproductive age, and this complaint which is one of the most widespread disorders in women is recognized by high androgen levels.^[21] Many of the women over 30 years in this study group may be suffering from polycystic ovary syndrome, which may be the cause of high testosterone levels. Uses of isotretinoin, an artificial optional of Vitamin A, is known to decrease the sebaceous secretions, and hence, it is used to prevent acne formation during adolescence, this may be explain decrease of acne formation in the mild group, since many of the patients uses this drugs.^[22] In conclusion,

the study found a significant association between serum testosterone and severity of AV and there was no correlation between the severity of AV and patients ages.

ACKNOWLEDGMENT

The authors are grateful for the subscribers for their contribution in this study.

REFERENCES

1. Thiboutot D, Gollnick H, Bettoli V, Dréno B, Kang S, Leyden JJ, *et al.* New insights into the management of acne: An update from the global alliance to improve outcomes in acne group. *J Am Acad Dermatol* 2009;60:S1-50.
2. Slayden SM, Moran C, Sams JW, Boots LR, Azziz R. Hyperandrogenemia in patients presenting with acne. *Fertil Steril* 2001;75:889-92-6.
3. Seirafi H, Farnaghi F, Vasheghani-Farahani A, Alirezaie NS, Esfahanian F, Firooz A, *et al.* Assessment of androgens in women with adult-onset acne. *Int J Dermatol* 2007;46:1188-91.
4. Borgia F, Cannavò S, Guarneri F, Cannavò SP, Vaccaro M, Guarneri B, *et al.* Correlation between endocrinological parameters and acne severity in adult women. *Acta Derm Venereol* 2004;84:201-4.
5. Arowajolu A. Azoula acne. In: James W, Berger TG, Elston D, editors. *Andrews Disease of the Skin Clinical Dermatology*. Philadelphia, PA: Saunders, Elsevier; 2011. p. 228-45.
6. Zaenglein A, Graber EM, Thiboutot DM, Strauss JS. Acne Vulgaris and Acneiform Eruptions. In: Dalam Wolff K, Goldsmith LA, Katz SI, editors. *Fitzpatrick's Dermatology in General Medicine*. 7th ed. New York: Mc Graw Hill; 2008.
7. Benner N, Sammons. Overview of the treatment of acne vulgaris. *ACOFD* 2013;5:185-90.
8. Titus S, Hodge J. Diagnosis and treatment of acne. *Am Fam Phys* 2012;86:734.
9. Jacob R, Jude AL, Chandrasekhar R, Sasikala K. Prevalence of Acne among women with poly cystic ovarian syndrome-a clinical study scrutiny. *Int Res J Health Med Sci* 2014;1:7-13.
10. Manzoor S, Rather S, Shahab-ud-din S, Sameen F, Aleem S, Jeelani S. The relationship between blood lipid profile and acne in non-obese, non-PCOS patients. *Int J Contemp Med Res* 2016;3:1096-9.
11. Zouboulis CC, Akamatsu H, Stephanek K, Orfanos CE. Androgens affect the activity of human sebocytes in culture in a manner dependent on the localization of the sebaceous glands and their effect is antagonized by spironolactone. *Skin Pharmacol* 1994;7:33-40.
12. Voegeli SK, Rey F, Reymond MJ, Meuwly JY, Gaillard RC, Gomez F. Androgen dependence of hirsutism, acne and alopecia in women. *Medicine* 2009;88:32-45.
13. Kushlinskii NE, Salamova IV, Masyukova SA, Muhammad AK, Degtyar VG, Samsonov VA. Sex hormone binding globulin, serum testosterone and androgen receptors in the skin in papulopustular and conglobata forms of acne vulgaris. *Bull Exp Biol Med* 1997;123:163-5.
14. Cibula D, Hill M, Vohradnikova O, Kuzel D, Fanta M, Zivny J. The role of androgens in determining acne severity in adult women. *Br J Dermatol* 2000;143:399-404.
15. Azziz R, Carmina E, Sawaya ME. Idiopathic hirsutism. *Endocr Rev* 2000;21:347-3.
16. Tietz NW editor. *Clinical Guide to Laboratory Tests*. 3rd ed. Philadelphia, PA: W.B. Saunders, Co.; 1995. p. 578-80.
17. Mills O, Porte M, Kligman A. Enhancement of comedogenic substances by ultraviolet radiation. *Br J Dermatol* 1978;98:145-50.
18. Vasudevan DM, Sreekumari S, Vaidyanathan K. *Textbook of Biochemistry for Medical Students*. 7th ed. New Delhi, London, Philadelphia, PA, Panama; Lippincott Williams and Wilkins; 2013. p. 468.
19. Gollnick H, Cunliffe W. Management of acne. *J Am Acad Dermatol* 2003;41:S1-38.
20. Baumann M. *Cosmetic Dermatology Principles and Practice*. New York: The McGraw-Hill Companies; 2002.
21. Lee AT, Zane LT. Dermatology manifestations of polycystic ovary syndrome. *Am J Chin Dermatol* 2007;8:201-19.
22. Lawrence D, Shaw M, Kats M. Elevated free testosterone in men and women with acne vulgaris. *Clin Exp Dermatol* 1986;2:263-73.