

REVIEW ARTICLE

A Review on Traditional and Alteranative Treatment For Skin Disease “Vitiligo”

Priyanka Soni*, Ravi Patidar, Vishal Soni, Sweta Soni

**Department of Herbal Drug Research, B.R. Nahata College of Pharmacy, Mandsaur, M.P. India.*

Received 18 June 2010; Accepted 9 Aug 2010

ABSTRACT

Vitiligo is a relatively common dermatologic finding and one that has been observed since ancient times. Vitiligo is characterized by white (depigmented) patches in the skin, caused by the loss of functioning melanocytes. The hair, and rarely the eyes may also lose colour. Vitiligo is a relatively common dermatologic finding and one that has been observed since ancient times. The cause of vitiligo remains unknown, although an autoimmune pathogenesis seems most likely. Treatment also remains difficult, allopathic are only suppressive therapy not curative. A number of new therapies show significant potential. In this review, we will focus on the traditional remedies, herbs reported as antivitaligo agents, surgical treatments, ayurvedic and alternative treatment for vitiligo.

Keywords: Epidermis/ transplantation, PUVA therapy, Vitiligo, treatment, skin disorder.

INTRODUCTION

Vitiligo is a hypopigmentation & acquired depigmentary disorder. Approximately 50% of the cases have the onset of their disease prior to the age of 20 years and 25% prior to the age of 14 years^[1]. Vitiligo is characterized by selective destruction of melanocytes of the basal layer of the epidermis and/or occasionally the hair follicle resulting in white patches on the skin, the mucous membranes and/or white hair^[2]. Regardless of age, sex and skin color^[3] people with this disorder can experience emotional stress, particularly if vitiligo develops on visible areas of the body, such as face, hands, arms, feet, or on the genitals^[4]. Theories concerning the cause of vitiligo have concentrated on three different mechanisms: autoimmune, autocytotoxic, and neural. The disorder has been reported in association with several endocrinopathies and other disorders of autoimmune nature^[5]. Vitiligo is not believed to be sex-linked, but 6-38% of patients have a positive family history. Allopathic are only suppressive therapy not curative i.e. it only cure the symptoms not the causes of the disease. Herb treatments that may provide some benefit include immune tonics and adrenal tonics, when these systems are weak. Because many skin problems are related to liver, bowel function, and food allergies, liver-regulating herbs and bowel-

strengthening herbs, as well as a continuous course of probiotics, may also be helpful^[6].

PATHOPHYSIOLOGY

The pathophysiological mechanism involves auto-immune and intrinsic factors that affect melanocyte survival, resulting in a loss of functional melanocytes in the epidermis. One hypothesis holds that the auto-immune destruction of melanocytes is responsible for vitiligo, a notion that is supported by the association of vitiligo with multiple auto-immune processes. In addition, circulating antibodies against melanocyte-specific antigens and cytotoxic T lymphocytes specific for melanocytes have been demonstrated. Further, many genetic markers for vitiligo are related to immunity. Alternative concepts include:

- Oxidative stress, specifically from hydrogen peroxide, in the setting of reduced cellular defense mechanisms.
- Inherent functional defect of melanocytes.
- Reduction of melanocytes due to dysregulation of their survival and apoptosis
- Toxicity from neurochemical transmitters.
- Viruses (e.g., CMV)^[7, 8].

ETIOLOGY

The etiology is unknown, but some theories have been used to explain the disease:

Auto-immunity - due to frequent associations with other auto-immune disease such as thyroiditis and type I diabetes, the presence of anti-melanocyte antibodies, and a response to immunosuppressant therapy;

Cytotoxicity - the possibility that metabolites formed during melanin synthesis may destroy melanocytes;

Neural - chemical mediators released at nerve endings might destroy melanocytes or inhibit melanin production;

Free radicals - excess free radicals might be toxic for melanocytes;

Convergent - a combination of these theories [8].

Genetic - There appears to be several genes (such as NALP1) that cause an individual to be susceptible for developing vitiligo. What these genes control is yet to be determined.

Triggering - It appears that some event must trigger the destruction of the pigment cells. There are many proposed triggers and they may not be the same for all vitiligo situations (such as sunburn, trauma, pregnancy, etc.).

Immune -The immune system can also be involved with the destruction of the pigment cells. That is why vitiligo is frequently referred to as an autoimmune disease [9].

The exact cause of vitiligo is not known. It is an autoimmune disease that is believed to be hereditary. The proposed theories are that stress, thyroid dysfunction, skin injury, severe sunburns, chemicals, and medicines combined with the genetic tendency towards vitiligo can all contribute to the condition. However these are theories that have not yet been substantiated [10].

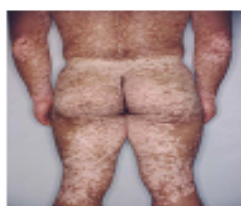

Fig.1 Generalized



Fig.2 Focal

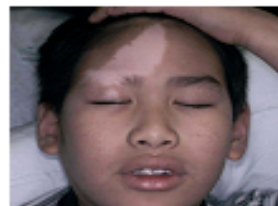

Fig.3 Unilateral (segmental)



Fig.4 Acrofacial

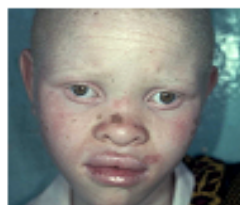

Fig.5 Total

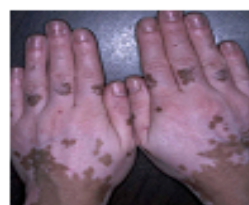

Fig. 6 Contact/Occupational

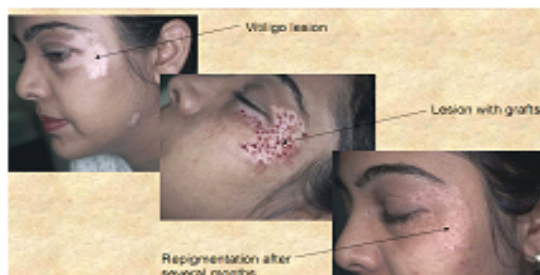

Fig. 7 Skin grafting/transplantation

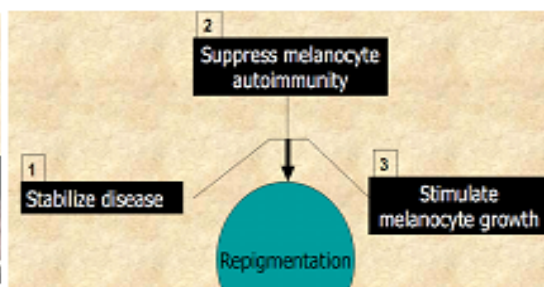


Fig. 8 Repigmentation Therapies

EPIDEMIOLOGY

Through worldwide in distribution, is very common in India, Egypt and other tropical countries. Because of its enigmatic character, vitiligo is tricky to treat especially when the disease is in the active progressive stage [11]. The distribution of vitiligo among the patients was 53.2% in males (n=74) and 46.8% in females (n=65). Among the total 139 patients 89 (64%) were from urban areas and the remaining 50 (36%) were from rural areas. The Mean \pm SD age of the patients was 25.06 ± 17.6 years. Occurs in

all global regions and ethnic groups with same frequency.

- Affects 0.1-8.8 % of the population.
- Of those who will get vitiligo, half show symptoms by 20yrs of age, 95% by 40yrs of age.
- Affects males & females equally.
- Frequent in family units with 7% incidence.
- There are various types of vitiligo classified by physicians [10,11]

CLASSIFICATION

Recognizing that not all vitiligo behaves in the same way or has the same characteristics, classification systems have been proposed for the last 50 years. We suggest that vitiligo can be divided into essentially two categories - generalized and segmental, with perihalo nevi as an adjunct. Segmental vitiligo is characterized by early onset, rapid progression and then persistence without change. There are no specific precipitating factors. The disease spreads in a linear fashion and may also lead to poliosis. An area roughly related to the trigeminal dermatome is the most commonly affected. Five subtypes were proposed. Importantly, they noted that segmental vitiligo of the face does not always follow Blaschko's lines, dermatomes or acupuncture lines^[11-12].

DIFFERENTIAL DIAGNOSIS

Diagnose of vitiligo, one must be able to differentiate between a complete absence of pigment, hypopigmentation and normal skin. This is more difficult in light-complexioned patients. Where vitiligo is classical, as in the symmetrical types, the diagnosis is straightforward and can be made with confidence in primary care^[12]. Wood's light may be of benefit in the diagnosis of vitiligo and in the demonstration of the extent and activity of the disease in subjects with skin types I and II. Wood's light can be of use in monitoring response to therapy. A blood test to check thyroid function should be considered in view of the high prevalence of autoimmune thyroid disease in adults with vitiligo^[13].

Equipment used for vitiligo diagnosis

- Pure tone and speech audiometer
- Sound treated room
- Cochlear Emission Analyzer Madsen
- Immittancemeter
- Evoked Response Audiometer Nickolet Compact four
- Wood's light lamp^[14].

TREATMENT

Treatment of vitiligo is often difficult and frustrating, both for the patient as well as the physician. Many modalities have been and continue to be used. The following therapies and their efficacy will be discussed: topical corticosteroids; topical immunomodulators; phototherapy including PUVA, topical PUVA, UVB and monochromatic excimer laser or light,

as well as microphototherapy; surgical options including autologous mini-punch grafting; blister roof grafting, and epidermal cell transplantation. The issue of bleaching accomplished by hydroquinone, monobenzene, or Q switched ruby laser will also be addressed. In determining efficacy of treatment, greater than 75% repigmentation is considered a cosmetically acceptable level of repigmentation.

MEDICAL TOPICAL CORTICOSTEROIDS

Topical corticosteroids are often used as therapy for vitiligo. A meta-analysis in 1998 found that class 3 and 4 corticosteroids resulted in more than 75% repigmentation of 56% of segmental vitiligo patients and 55% of generalized vitiligo patients. In 1999, the same group made an attempt to establish evidence based guidelines for treatment of vitiligo in children and adults. Another meta-analysis of the literature was performed, which again showed that class 3 corticosteroids are the most effective and safest therapy for segmental vitiligo.

TOPICAL IMMUNOMODULATORS

With the introduction of topical immunomodulators (tacrolimus and pimecrolimus), many had hoped they would be a panacea for a number of cutaneous disorders, including vitiligo. A number of studies have shown their efficacy or near-efficacy to topical corticosteroids, without the attendant adverse effects, such as atrophy. With new concerns regarding their long-term safety, the topical immunomodulators may best be used to treat small and/or difficult areas, such as the eyelids. An interesting report of focal hypertrichosis in a child while using topical tacrolimus for vitiligo was recently described.

SYSTEMIC PUVA

Photochemotherapy (PUVA) was originally developed in the 1940's by an Egyptian physician for the treatment of vitiligo. It has subsequently been used for many different cutaneous disorders. Repigmentation with PUVA is widely variable and rarely is 100% achieved. In general, dark skin types have better repigmentation than paler skin types. Usually, one to three years of treatment are needed for optimal results, which is one of the drawbacks. PUVA has the highest rates of adverse effects among nonsurgical treatments, such as nausea, vomiting, phototoxic reactions and a theoretical increased long-term cutaneous malignancy risk. For these

reasons, this method is not being used as often for vitiligo, particularly in the United States.

TOPICAL PUVA

Topical PUVA is an attempt to limit the area that becomes photosensitized and avoid some of the effects of systemic psoralen. This method also has side effects, including erythema, blistering and hyperpigmentation of normal, adjacent skin. When topical PUVA was compared to narrowband UVB in the treatment of generalized vitiligo, the therapies were found to be comparable, but narrowband UVB had fewer adverse effects and less cumulative UVB dose.

NARROWBAND UVB

Narrowband UVB for the treatment of generalized vitiligo in children has recently emerged as a promising therapy. A meta-analysis in 1999 found that narrowband UVB was the most effective and safest therapy for generalized vitiligo. Subsequently a number of open trials in children with generalized vitiligo have been conducted, with the best results on the face and neck and in vitiligo present for a shorter duration. Hands and feet show little response. Treatment three times per week seems to have a somewhat better response than twice per week.

MICROPHOTOTHERAPY - UVB

A variation of narrowband UVB, microphototherapy has been used to treat both segmental and non-segmental vitiligo. The beam is focused only on areas affected by vitiligo. An open trial of adults and children with both segmental and generalized vitiligo were treated with this modality. Seventy percent achieved normal pigmentation in greater than 75% of treated areas. This may be the treatment of choice in patients with <30% BSA (body surface area) involvement and the best treatment for children, as the cumulative dose of radiation is very low and non-affected skin does not become hyperpigmented.

MONOCHROMATIC EXCIMER LIGHT (MEL)

Monochromatic excimer light (MEL) has been used to treat adults with either segmental or generalized vitiligo. Good results were found, with 95% of patients showing some repigmentation and approximately 50% greater than 75% repigmentation. Significantly, three patients responded to MEL who had not responded to narrowband UVB in the past.

The results are similar to those with excimer laser; however, MEL has the advantage of lower power density leading to reduced risk of overexposure, the possibility to treat larger areas at a time, and shorter treatment duration. These advantages may allow this method to be useful in children, however it has unknown efficacy, as no children under 15 years were treated in this study.

Surgical EPIDERMAL GRAFTING (autologous mini-punch grafting, blister roof grafting)

Surgical methods offer other options in the treatment of vitiligo. Segmental vitiligo is the best indication for surgical repigmentation and these patients are good candidates for epidermal grafting. A retrospective case series of 143 patients treated with suction blister epidermal grafting showed the best results in segmental subtypes, and in patients less than 20 years old. However, no children less than 10 years were included in the study. Significantly, localization of the vitiliginous area did not affect treatment outcome, as it often does in medical therapies such as narrowband UVB phototherapy. A comparison of mini-punch grafting and splitskin grafting in chronic, stable, segmental vitiligo showed better results with split-skin grafting, particularly over the face and extremities.

EPIDERMAL CELL TRANSPLANTATION

There are limitations to autologous mini-punch grafting and blister roof grafting, primarily a cobblestone appearance and limited treatment area per session. Therefore, epidermal cell transplantation has been investigated as a treatment option. A recent study of epidermal cell transplantation found that the best results are seen in segmental vitiligo, with some improvement for those with generalized vitiligo. In this technique, a melanocyte-rich suspension is applied to the affected area and then allowed to graft. The best results are seen when only one site is involved. The main advantage to this technique is that only one time treatment is necessary, if successful.

COSMETIC COVERUPS

If all treatments have failed; the patient does not wish to undergo treatment; or while treatment is ongoing, cosmetic coverups can be very useful. A recent study investigated quality of life in vitiligo patients and the effect of using camouflage. Using camouflage, particularly for the face, head and neck improved the patients' quality of life, especially for “feelings of

embarrassment and self consciousness" and "choice of clothing". A number of brands are available including Dermablend, Covermark, Derma Color, Dermage, and Elizabeth Arden Concealing Cream.

Bleaching

Finally, in adults, bleaching of remaining pigmented skin may be considered. Emphasis must be made that this is NOT recommended for children. The child may not fully comprehend the permanent depigmentation of monobenzyl ether of hydroquinone (monobenzone), or the Q switched ruby laser, or even the fading effect of hydroquinone.

with generalized vitiligo. Treatment of vitiligo depends on subtype and age, with a number of promising treatments for children on the horizon, including narrow-band UVB phototherapy and surgical techniques^[13-15].

TRADITIONAL REMEDIES FOR TREATMENT OF VITILIGO

Psoralea seeds should be steeped in the juice of ginger or cow's urine for three days. The fluids should be renewed every day. The seeds should then be rubbed with hands to remove their husks, dried in the shade and powdered. One gram of this powder should be taken every day with fresh milk for 40 days continuously. The ground seeds should also be applied to the white spots^[16].

Babchi seeds, combined with **Tamarind seeds**, are also useful. Equal quantity of both the seeds should be steeped in water for three to four days. They should then be shelled and dried in the shade. They should be ground into paste and applied to the white patches for a week. If the application of this paste causes itching or the white spots become red and a fluid begins to ooze out, it should be discontinued. If there is no itching or reddening, babchi seeds should be taken also for 40 days.

Red clay used for leucoderma is found by the river side or on hill slopes. The clay should be mixed in ginger juice and applied over the white spots once a day. The copper contained in the clay seems to bring back skin pigmentation and ginger juice serves as a milk stimulant, facilitating increased blood flow to the spots.

Radish seeds paste of the is valuable in treating leucoderma. About 35 grams of these seeds should be powdered in vinegar and applied on the white patches. For better results, seeds should be finely pounded, mixed with a little white arsenic

and soaked in vinegar at night. After two hours, when leaves appear, it should be rubbed on the leucoderma patches.

Turmeric and Mustard oil is also considered beneficial in the treatment of leucoderma. About 500 gm, of turmeric should be pounded and soaked in eight kg of water at night. It should be heated in the morning till only one kg of water is left. It should then be strained and mixed with 500 gm of mustard oil. This mixture should be heated till only the oil is left. It should be applied on white patches every morning and evening for a few months^[17].

TREATMENT IN TRADITIONAL SIDDHA MEDICINE

Vitiligo has emerged as a threatening disease especially in the Tropical countries. It is also evident that those who suffer from Vitiligo develop inferiority complex. In the author's clinical observation,

- Professional hair dressers,
- Those who use pesticides in their agricultural lands,
- Those who have the regular habit of hair dyeing and
- Those who wear footwear made out of cheap rubber tyres are more prone for this disease.

Special notes regarding Vitiligo are found in many Siddha literatures and manuscripts. The formulation aroused out of the author's clinical experience cures Vitiligo completely^[18]. The important herbs that cure Vitiligo are listed below.

1) *Aristolochia indica*, Linn (Family: *Aristolochiaceae*).

According to Siddha literatures, this plant has curative effects in cardiac diseases, delirium, toxic type of dropsy / anasarca (Visha sobai), malarial fever (Kulir suram), Anemia, Scabies, Allergy, Body and joint pains and amenorrhoea. Apart from these properties, the root of *Aristolochia* is highly effective against Vitiligo.

2) *Tribulus terrestris*, Linn (Family: *Zygophyllaceae*)

Siddha system identifies various types of Tribulus. The fact that tribulus has 'Photo helium' property was first revealed by ancient Tamil literatures some 2000 years ago. This fact comes to light through the Tamil Literatures "Aga Nanooru and Pura Nanooru and Seevaga Sinthamani. is one among the important types of Tribulus. According to the Siddha text, 'Pathartha Guna Chinthamani', it removes Megha diseases and Vitiligo^[19].

3) *Thespesia populnea*, *Corr.* (Family – *Malvaceae*)

Siddha literatures, the root of hundred years old *Thespesia* has the power of curing chronic Leprosy. Siddha text 'Agasthiyar Gunavagadam' claims that *Thespesia* cures skin diseases, pain arising out of bites, Ascitis, dropsy, eczema and venereal diseases. The matured inner bark of *Thespesia*, when chewed, cures Vitiligo occurring in the lips. Some other specific herbs, given in the form of 'Chooranam' (fine powder) cures Vitiligo and restores the normal skin colour^[20].

Homeopathic Treatment

Homeopathy treats the person as a whole. It means that homeopathic treatment focuses on the patient as a person, as well as his pathological condition. The homeopathic medicines are selected after a full individualizing examination and case-analysis, which includes the medical history of the patient, physical and mental constitution etc. A miasmatic tendency (predisposition/susceptibility) is also often taken into account for the treatment of chronic conditions. The medicines given below indicate the therapeutic affinity but this is not a complete and definite guide to the treatment of this condition. The symptoms listed against each medicine may not be directly related to this disease because in homeopathy general symptoms and constitutional indications are also taken into account for selecting a remedy^[21].

Homeopathic Remedies

Ars.alb, Ars.sulph.flavum, Bacillinum. Graphites, Mercsol, Nat.mur, Nit.acid, Nux vom, Phos. Sep, Sil, Sulph, Thuja.

Yoga Therapy

Ideally kapalbhati should be done in the morning in empty stomach, if early morning is a problem then it should be performed after 3-4 hours of meal. One should sit in sukhasana or padmasana and should inhale passively and exhale forcefully. This provides aeration to blood circulation. Even a handicapped who is unable to sit in padmasana can do it sitting on the chair with straight spine. Inhalation and exhalation should be from nostril and abdominal muscles should come into act. Kapalbhati purifies blood circulation by aerating it and has been extremely beneficial in skin treatment like skin psoriasis, eczema, allergies, leucoderma, vitiligo. It has a wonderful effect and is a miracle for acne treatment several mental disorders including anxiety, depression and even schizophrenia had been cured by this asana^[22].

Ayurvedic Treatment

Ayurveda is the most ancient system of medicine. According to Ayurveda Vitiligo & Leucoderma are termed 'Kilas'. It is further known as 'Darun', 'Charun' and 'Switr' as this is tridosha. It is a skin disorder mainly due to inappropriate diet combination intake regularly and formed due to disturbance of tridoashas namely 'Vaata', 'Pitta' and 'Kapha'. After aggravation it moves & affects to rakta, mans and med dhatus. Vitiligo cure can be achieved with ancient Ayurvedic herbs which are basically meant for treating the root cause of diseases. As Ayurveda enhances immunity power by improving metabolism of the body, lack of which is the only known reason for Vitiligo & Leucoderma. This theory is well applicable in complete vitiligo cure and leucoderma cure also as ancient Ayurveda is a treasure of different herbal combinations which can really cure vitiligo & leucoderma as in both the condition auto immunity is the basic reason. . While treatment, a patient's immunity power is also developed with the help of our herbal immunostimulators to such extent so that the patient's body can counteract to any disease causing agents such as Bacteria, Viruses, and Parasites etc^[23]. Only four points has to be considered & remembered for full Vitiligo cure & Leucoderma cure which are

1. To choose correct ayurvedic medicines.
2. To have patience & to develop positive thinking.
3. To strictly follow dietary restrictions.
- 4 To have faith in the treatment.

Herbs Reported for Treatment of Vitiligo

Vitiligo is a depigmentation or whitening of the skin, possibly due to an autoimmune disorder. There is no satisfactory treatment or cure. Herb treatments that may provide some benefit include immune tonics and adrenal tonics, when these systems are weak. Because many skin problems are related to liver, bowel function, and food allergies, liver-regulating herbs and bowel-strengthening herbs, as well as a continuous course of probiotics, may also be helpful. Herbs which are reported as antivitaligo agents are mentioned in **Table no 1**.

PREVENTIVE MEASURES

The patient should avoid tea, coffee, alcoholic beverages and all condiments and highly flavored dishes

CONCLUSION

In conclusion, vitiligo is a hypopigmented and autoimmune disorder causes the formation of white patches on the skin. There is no satisfactory treatment or cure. Herb

treatments that may provide some benefit include immune tonics and adrenal tonics, when these systems are weak. Because many skin problems are related to liver, bowel function, and food

allergies, liver-regulating herbs and bowel-strengthening herbs, as well as a continuous course of probiotics, may also be helpful.

Table No. 1 Herbs used in treatment of vitiligo^[23]

S.No.	Herbs biological name	Common Name	Part used	Treatment support
1	<i>Plumbago indica</i> (Plumbaginaceae)	Chitraka	Root and bark	Vitiligo skin
2	<i>Psoralea corylifolia</i> (Fabaceae)	Bakuci	Seeds, root, leaves	alleviates vitiligo
3	<i>Semecarpus anacardium</i> (Anacardiaceae)	Bhallataka	Nuts, oil, flowers	Nuts crushed with cow urine
4	<i>Terminalia bellerica</i> (Combretaceae)	Bibhitaka	Fruit and seed	Vitiligo skin
5	<i>Nigellasativa</i> (Ranunculaceae)	Kalonji	seeds and oil	Vitiligo skin
6	<i>Ginkgo biloba</i> (<i>Ginkgoaceae</i>)	Ginkgo	extract 40 mg three times per day for up to six months	repigmentation
7	<i>Picrorhiza</i>	Gentian	400-1500 mg as powdered encapsulated /day	repigmentation
8	<i>Zingiber officinale</i> (<i>Zingiberaceae</i>)	Ginger	tincture, tea, tablet, capsule	bowel strengthening
9	<i>Ammi visnaga</i> (Apiaceae)	<i>Khella</i>	tincture, internally and externally	pigmentation enhancer
10	<i>Milk Thistle</i> (Asteraceae)		tablet, tincture, capsule c	liver protectant, tonic
11	<i>Tribulus terrestris</i> (Zygophyllaceae)	Gokhru	Fruit powder	repigmentation
12	<i>Azadirachta indica</i> family (Meliaceae)	Neem	Leaves	repigmentation
13	<i>Picrorhiza kurrooa</i>		Picrolex	repigmentation
14	<i>Ammi majus</i> (Apiaceae)	<i>Bishop's Weed</i>	Fruits	repigmentation

REFERENCE

- Arican O, Kurutas EB. Oxidative stress in the blood of patients with active localized vitiligo. *Acta Dermatoven APA*, 2008; 17: 12-16.
- Kakourou T, Alzolibani A, Kakourou T. Vitiligo in children. *World J Pediatric*, 2009; 5: 265-268.
- Alzolibani A. Genetic epidemiology and heritability of vitiligo in the Qassim region of Saudi Arabia. *Acta Dermatoven APA*, 2009; 18:119-125.
- Ahmed I, Ahmed S, Sarwat N. Frequency and pattern of psychiatric disorder in patients in with vitiligo. *J Ayub Med Coll Abbottabad*, 2007;19: 3.
- Al-Mutairi N & Ashok KS. Profile of Vitiligo in Farwaniya Region in Kuwait. *Kuwait Medical Journal*, 2006;38(2): 128-131.
- Mukhejee KP, Quality control of herbal drugs as approach to evaluation of Botanicals; Pharmacological screening of herbal drug, Bussiness horizon, new Dehli, India 2005;191-197.
- Rajpal S, Atal R. Clinical profile and management pattern of vitiligo. *Journal of Clinical and Diagnostic Research*, 2008;(2):1065-1068.
- Jane SB, Neil S Prose. Vitiligo in children: a review of classification, hypotheses of pathogenesis and treatment. *An Bras Dermato*, 2005; 80(6):633-7.
- Fransiscus A., “HCV – Extra hepatic Manifestations: Vitiligo”. HCSF Version 2009; 1:2.
- Boissy RE “Vitiligo” *Vitiligo Newsletter*, 2002; 8.
- Behl PN, Banerji S. Active Progressive Vititlgo – Clinical and Histopathological Response to Different Therapeutic Regimens. *Dermatology times*, 1982; 2: 1-4.
- Huggins RH, Schwartz RA, Janniger CK. “Vitiligo”. *Acta Dermatoven APA*, V, 2005;14:137-145.
- Gawkrodger DJ, Ormerod AD, Shaw L, Mauri-Sole I, Whitton MJ, Anstey AV,

- Ingham J. and Young K. Guideline for the diagnosis and management of vitiligo. *British Journal of Dermatology*, 2008;1051–1076.
14. Talia K. Vitiligo in children: a review of classification, hypotheses of pathogenesis and treatment. *World J Pediatric*, 2009; (4):265-268.
 15. Dalia AB. Punch Grafting in Vitiligo. Different Factors which Affect the Results *J Egypt Women Dermatol Soc*, 2010;7:16-21.
 16. Khurana A. Detailed Review: Tacrolimus in Vitiligo Department of Dermatology & STD, UCMS & GTB. *Hospital Int J Dermatol*, 2009 ;48(1):86-90.
 17. Tiwari SK. Evaluation of the efficacy of *Dhatrayadi Yoga* (Internal) and *Avalgujadi lepa* (external) along with and without *sodhana (Vamana)* in *Switra* with special reference to Vitiligo. Post graduation and research center Kayachikitsa, 1998-2001.
 18. Anonymous, <http://www.ayurhealthline.com> open document10/04/2007..
 19. Anonymous, http://www.best-homremedies.com/skin_disorders/leucoderma/ open document10/04/2007.
 20. Anonymous, <http://health.hpathy.com/vitiligo-leucoderma-symptoms-treatment-cure.asp> open document 10/04/2007.
 21. Rafael F, Maria IB. Update on skin repigmentation therapies in vitiligo, *Pigment Cell Melanoma Res*, 2008;22 ; 42–65.
 22. Bhushan P, Narvind C, Ashok D, Vaidya B, Herbal remedies and the bias against Ayurveda. *Current science*, 2003;(84):9-10.
 23. Anonymous, [http://www.India study channel. Com resources 48654 – Yoga – Kapalbhati - pranayama – for – skin - diseases. aspx](http://www.india-study-channel.com/resources/48654-Yoga-Kapalbhati-pranayama-for-skin-diseases.aspx) open document10/04/2007.